

# Kategorie:Dávno zkontrolované články

V této kategorii jsou zařazeny články, od jejichž poslední kontroly učitelem uplynuly více než 3 roky.

## Pages in category "Dávno zkontrolované články"

The following 200 pages are in this category, out of 879 total.

(previous page) (next page)

### A

- Abbeho teorie
- Ablace
- Absorbance
- Absorpce, Lambertův zákon
- Achondroplázie
- Acidóza (rozcestník)
- Adamsův-Oliverův syndrom
- Adenokarcinom tlustého střeva (preparát)
- Adenylátcykláza
- Adrenalin
- Aferentní
- Aglutinace
- Aglutinin
- Aglutinogen
- Agonista
- Agranulocyty
- Akustika
- Akutní hemoragická nekróza pankreatu (preparát)
- Akutní pankreatitida (laboratorní diagnostika)
- Akční a sumační potenciály
- Albumin
- Albuminurie
- Aldosteron
- Alely
- Alfa-dextrin
- Alkalóza (rozcestník)
- Aloplastika
- Ambulantní ošetření popáleniny
- Amniocentéza
- Amylolytický
- Amyláza
- Amyláza (heslo)
- Aneurysma mozkové arterie (preparát)
- Angiografie
- Anoxie
- Antagonista
- Anterográdní
- Antiport
- Antitrombin III
- Aorta
- Aorta abdominalis
- Aorta thoracica
- Aplasia fibulae congenita
- Aplikace injekcí
- Arabidopsis thaliana
- Arachnodaktylie
- Arsenazo III
- Arteria carotis communis
- Arteria carotis externa
- Arthrogryposis multiplex congenita
- Artroskopie
- Asfyxie
- Asistence u převazu
- Asociační studie
- Ateroskleróza
- Ateroskleróza koronární arterie (preparát)
- Portál:Atlas histologických preparátů/Endokrinní systém
- Portál:Atlas histologických preparátů/GIT
- Portál:Atlas histologických preparátů/Koční systém

- Portál:Atlas histologických preparátů/Koční systém
- Portál:Atlas histologických preparátů/Močový systém
- Portál:Atlas histologických preparátů/Mužský pohlavní systém
- Portál:Atlas histologických preparátů/Ženský pohlavní systém
- Portál:Atlas patologických karyotypů (1. LF UK)
- Atropin
- Audiometrie (2. LF UK)
- Audiometrie (biofyzika)
- Automatické pipety
- Autosomálně dominantní dědičnost
- Autosomálně recesivní dědičnost
- Axolemma

## B

- Baktericidní
- Bakteriofág (heslo)
- Bakteriální endokarditis (preparát)
- Barevnost látek
- Barevná hodnota erytrocytu
- Barva zvuku
- Barvení chromozomů
- Basaliom (preparát)
- Batmotropie
- Bazocytopenie
- Bazofilie
- Bazofilní granulocyt
- Beta-karoten
- Biliverdin
- Biofeedback
- Biofyzika sluchu
- Biologický monitoring
- Biotin
- Biuret
- Biuretová reakce
- Bloomův syndrom
- BMI
- Bolesti zad, kořenové syndromy na dolních končetinách/PGS
- Brachyterapie
- Bradykardie
- Bradypnoe
- Bromouracil
- Bromtymolová modř
- Burzitidy
- Bílkoviny v séru a moči (1. LF UK, VL)

## C

- Caenorhabditis elegans
- Celková bílkovina
- Celková tělesná voda
- Celokeramická náhrada
- Centrifugace
- Centromera
- Centromerický index
- Charakteristiky biosignálů
- Charakteristiky elektrických biosignálů
- Chemotaxe
- Chirurgické instrumentárium (zubní lékařství)
- Chlopenní vady/Repetitorium
- Cholesterolosis vesicae felleae (preparát)
- Chondrom (preparát)
- Choriokarcinom (preparát)
- Chromatografie na tenké vrstvě
- Chromozom
- Chromozom X
- Chromozom Y
- Chromozomální abnormality
- Chronická gastritis (preparát)
- Chronotropie
- Chymotrypsin ve stolici
- Círhóza pseudolobulární (preparát)
- Cirkadiánní rytmus
- Cirkulační šok/Repetitorium
- Clavicula

- Clearance
- Compartment syndrom
- Comptonův jev - co dokazuje, přínos
- Coomassie brilliant blue G 250
- Coulombův zákon a permitivita prostředí
- CTA koronárních tepen
- Cystadenoma mucinosum ovarii (preparát)
- Cytoplazma
- Cytoskelet z pohledu biofyziky
- Cytotoxicita
- Céliakie
- Cévní náhrady

## D

- Dechové testy s uhlíkem-13
- Dechové testy s vodíkem
- Dechový test s D-xylózou značenou uhlíkem-13
- Dechový test s močovinou značenou uhlíkem-13
- Dechový test s oktanoátem sodným značeným uhlíkem-13
- Denní osvětlení
- Depolarizace
- Deriváty hemoglobinu
- Deriváty hemoglobinu/Spektrofotometrie derivátů hemoglobinu
- Dermatoskopie
- Destičková granula
- Destičková zátka
- Detekce antigenu Helicobacter pylori ve stolici
- Detekce obrazu
- Dezinfekce a sterilizace
- DGGE
- Diagnostické užití ultrazvuku
- Diagnostické zobrazovací metody při náhlých příhodách břišních
- Diagnostické zobrazovací metody při vyšetření hrudníku
- Diagnostické zobrazovací metody při vyšetření pankreatu, jater a sleziny
- Diagnostické zobrazovací metody při vyšetření retroperitonea
- Diagnostické zobrazovací metody při vyšetření skeletu a kloubů
- Diagnostické zobrazovací metody při vyšetření zažívacího traktu
- Diagnostické zobrazovací metody v ORL
- Diagnostika helicobakterové infekce
- Diapedéza
- Diferenciace
- Diferenciální zesilovač
- Diferenciálně diagnostická rozvaha v neurologii/PGS
- DiGeorgův syndrom
- Dihybridismus
- Distenze
- Dobře diferencovaný uroteliální papilokarcinom (preparát)
- Dodecylsírán sodný
- Dopplerovská echokardiografie
- Dopplerovská ultrasonografie
- Dopplerovská ultrasonografie v medicíně
- Dopplerovská zobrazení
- Dopplerovský průtokoměr
- Downův syndrom
- Dromotropie
- Druhy potravin
- Druhy ran
- Dvojčecí metoda
- Dvoudobý dvoufázový otisk
- Dysbetalipoproteinémie
- Dyspareunie a algopareunie
- Dědičnost krevně skupinových systémů

## E

- Echogenita tkání
- Echokardiografie
- Edwardsův syndrom
- Edwardsův vzorec
- Edém mozku, poruchy HEB/Repetitorium
- Edém plic (preparát)
- Eferentní
- Ehlers-Danlosův syndrom
- Ejekční frakce

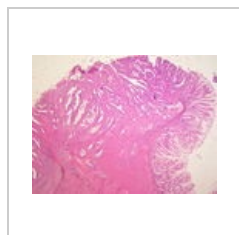
- Procvičování:EKG (1. LF UK)
- Elastické vlastnosti tkání
- Elastografie
- Elastomery

(previous page) (next page)

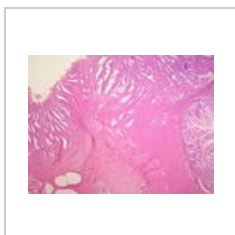
## Media in category "Dávno zkontrolované články"

The following 200 files are in this category, out of 205 total.

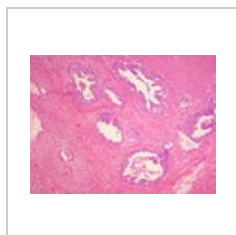(previous page) (next page)



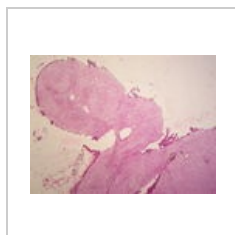
Adenokarcinom t...  
3,264 × 2,448;  
1.63 MB



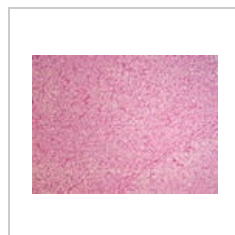Adenokarcinom t...  
3,264 × 2,448;  
1.61 MB



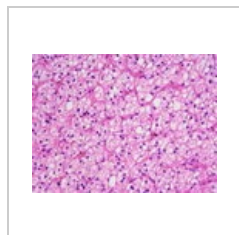
Adenokarcinom t...  
3,264 × 2,448;  
1.36 MB



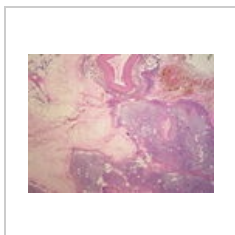
Adenom nadledvi...  
3,264 × 2,448;  
1.42 MB



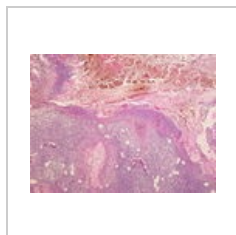
Adenom nadledvi...  
3,264 × 2,448;  
1.31 MB



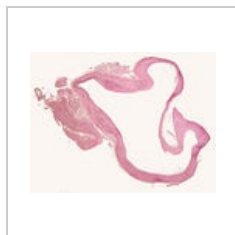
Adenom nadledvi...  
3,264 × 2,448;  
1.39 MB



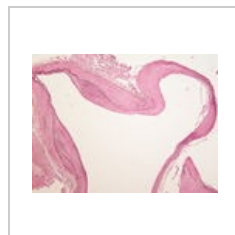
Akutní hemoragi...  
3,264 × 2,448;  
1.77 MB



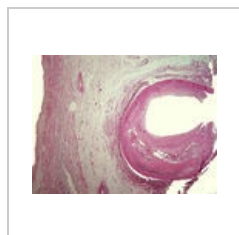
Akutní hemoragi...  
3,264 × 2,448;  
1.34 MB



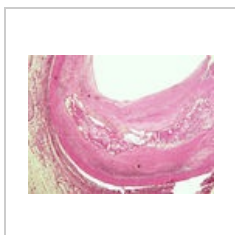
Aneurysma mozk...  
2,800 × 2,132; 625  
KB



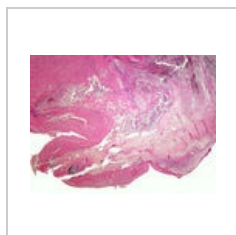
Aneurysma mozk...  
3,264 × 2,448;  
1.55 MB



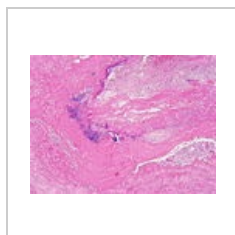
Ateroskleróza kor...  
3,264 × 2,448; 3  
MB



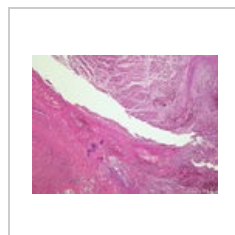
Ateroskleróza kor...  
3,264 × 2,448;  
3.13 MB



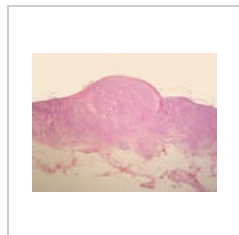
Bakteriální endok...  
3,264 × 2,448;  
3.48 MB



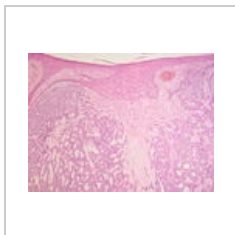
Bakteriální endok...  
3,264 × 2,448;  
4.54 MB



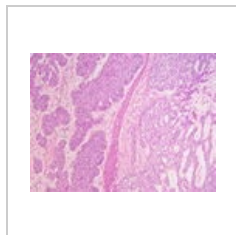
Bakteriální endok...  
3,264 × 2,448;  
4.57 MB



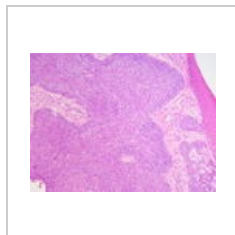Bazaliom (81A).jpg  
3,264 × 2,448;  
1.75 MB



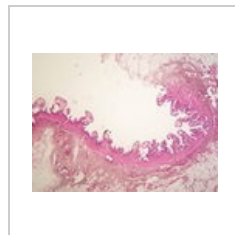
Bazaliom (81B).jpg  
3,264 × 2,448;  
1.51 MB



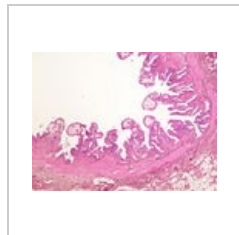
Bazaliom (81C).jpg  
3,264 × 2,448;  
1.38 MB



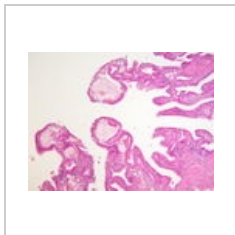
Bazaliom (81D).jpg  
3,264 × 2,448; 1.4  
MB



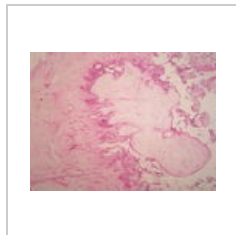
Cholesterolosis v...  
3,264 × 2,448;  
1.39 MB



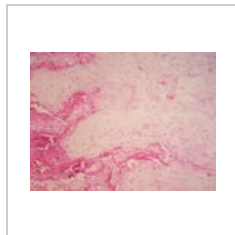
Cholesterolosis v...  
3,264 × 2,448;  
1.38 MB



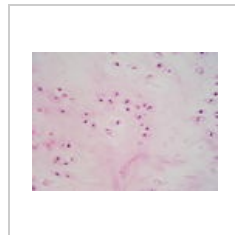
Cholesterolosis v...  
3,264 × 2,448;  
1.56 MB



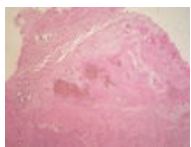
Chondrom (22A)....  
3,264 × 2,448;  
1.43 MB



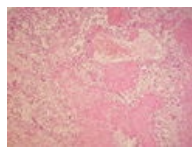
Chondrom (22B)....  
3,264 × 2,448;  
1.75 MB



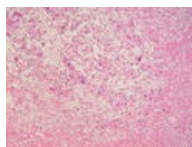
Chondrom (22C)....  
3,264 × 2,448;  
1.76 MB



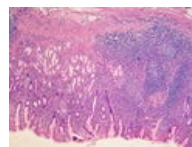
Choriokarcinom (...  
3,264 × 2,448;  
1.45 MB



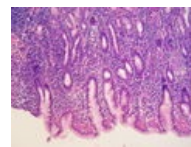
Choriokarcinom (...  
3,264 × 2,448;  
1.57 MB



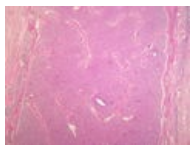
Choriokarcinom (...  
3,264 × 2,448;  
1.36 MB



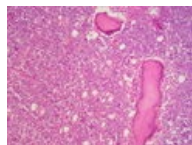Chronická gastrit...  
3,264 × 2,448; 4.1  
MB



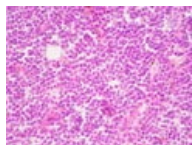
Chronická gastrit...  
3,264 × 2,448;  
3.61 MB



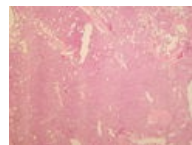
Chronická lymfad...  
3,264 × 2,448;  
4.13 MB



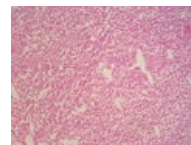
Chronická lymfad...  
3,264 × 2,448;  
1.61 MB



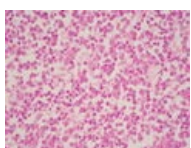
Chronická lymfad...  
3,264 × 2,448;  
1.56 MB



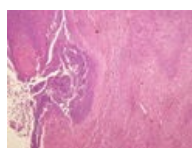
Chronická myeló...  
3,264 × 2,448; 1.7  
MB



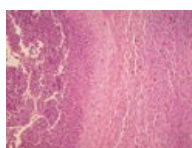
Chronická myeló...  
3,264 × 2,448;  
1.36 MB



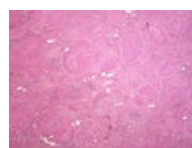
Chronická myeló...  
3,264 × 2,448;  
1.59 MB



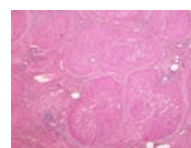
Chronický absces...  
3,264 × 2,448;  
1.34 MB



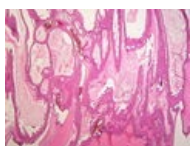
Chronický absces...  
3,264 × 2,448;  
1.29 MB



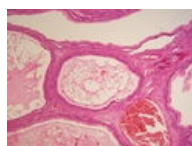
Cirhóza (41A).jpg  
3,264 × 2,448; 1.3  
MB



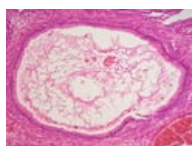
Cirhóza (41B).jpg  
3,264 × 2,448;  
1.34 MB



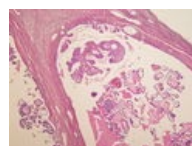
Cystadenoma m...  
3,264 × 2,448;  
1.71 MB



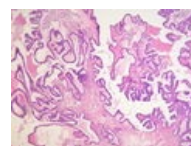
Cystadenoma m...  
3,264 × 2,448;  
1.54 MB



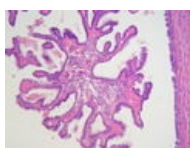
Cystadenoma m...  
3,264 × 2,448;  
1.62 MB



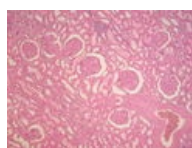
Cystadenoma ser...  
3,264 × 2,448;  
1.51 MB



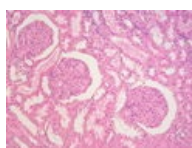
Cystadenoma ser...  
3,264 × 2,448;  
1.51 MB



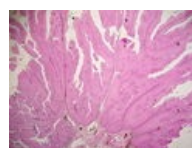
Cystadenoma ser...  
3,264 × 2,448;  
1.78 MB



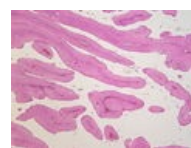
Diabetická glome...  
3,264 × 2,448;  
1.35 MB



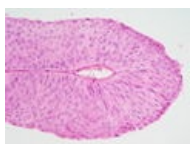
Diabetická glome...  
3,264 × 2,448;  
1.47 MB



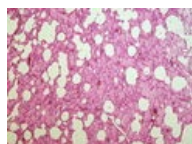
Dobře diferencov...  
3,264 × 2,448;  
1.73 MB



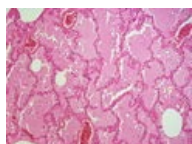
Dobře diferencov...  
3,264 × 2,448;  
1.36 MB



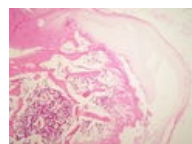Dobře diferencov...  
3,264 × 2,448;  
1.67 MB



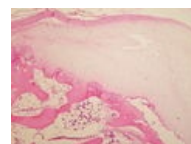
Edém plic (10A).j...  
3,264 × 2,448;  
3.69 MB



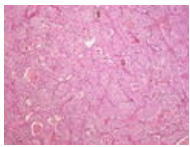
Edém plic (10B).j...  
3,264 × 2,448;  
3.28 MB



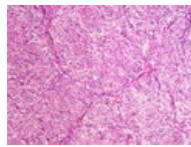
Exostosis cartilag...  
3,264 × 2,448;  
3.29 MB



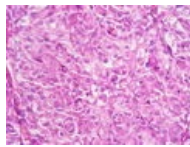
Exostosis cartilag...  
3,264 × 2,448;  
3.08 MB



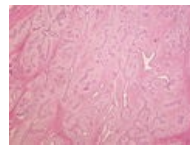
Feochromocytom...  
3,264 × 2,448;  
1.32 MB



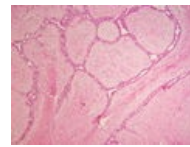
Feochromocytom...  
3,264 × 2,448;  
3.41 MB



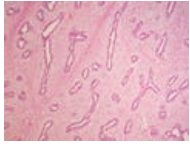
Feochromocytom...  
3,264 × 2,448; 1.4  
MB



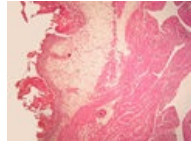
Fibroadenom ma...  
3,264 × 2,448;  
1.68 MB



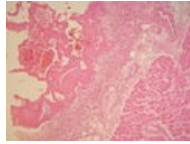
Fibroadenom ma...  
3,264 × 2,448;  
1.36 MB



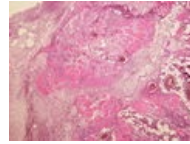
Fibroadenom ma...  
3,264 × 2,448;  
1.54 MB



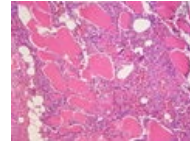
Fibrózní perikardi...  
3,264 × 2,448;  
2.53 MB



Fibrózní perikardi...  
3,264 × 2,448;  
1.42 MB



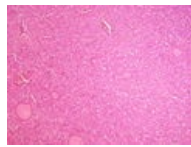
Flegmóna koster...  
3,264 × 2,448;  
4.52 MB



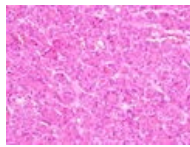
Flegmóna koster...  
3,264 × 2,448;  
1.34 MB



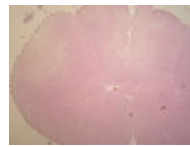
Folikulární karcin...  
3,264 × 2,448;  
3.45 MB



Folikulární karcin...  
3,264 × 2,448;  
4.51 MB



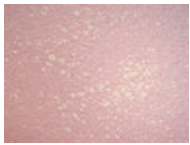
Folikulární karcin...  
3,264 × 2,448;  
3.56 MB



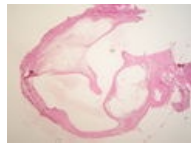
Funikulární myel...  
3,264 × 2,448;  
1.37 MB



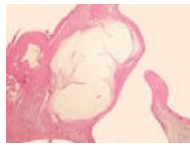
Funikulární myel...  
3,264 × 2,448;  
1.63 MB



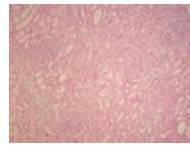
Funikulární myel...  
3,264 × 2,448;  
1.44 MB



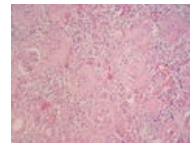
Ganglion (74A).jpg  
3,264 × 2,448;  
1.84 MB



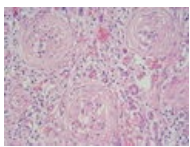
Ganglion (74B).jpg  
3,264 × 2,448;  
1.41 MB



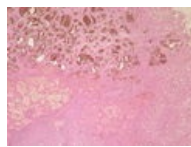
Glomerulonefritis...  
3,264 × 2,448;  
1.56 MB



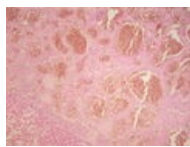
Glomerulonefritis...  
3,264 × 2,448;  
1.44 MB



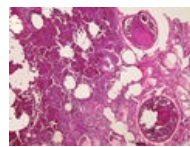
Glomerulonefritis...  
3,264 × 2,448;  
1.56 MB



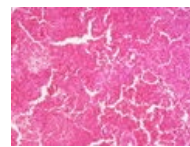
Hemangiom jater...  
3,264 × 2,448;  
1.62 MB



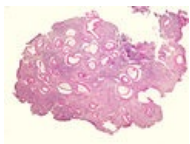
Hemangiom jater...  
3,264 × 2,448;  
1.31 MB



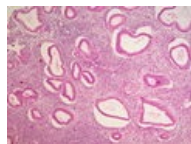
Hemoragický infa...  
3,264 × 2,448;  
3.55 MB



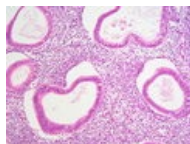Hemoragický infa...  
3,264 × 2,448;  
4.57 MB



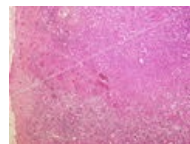Hyperplastické e...  
3,264 × 2,448;  
2.22 MB



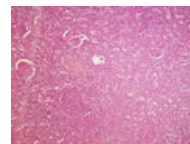
Hyperplastické e...  
3,264 × 2,448;  
1.75 MB



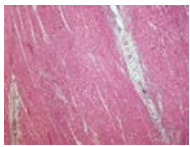
Hyperplastické e...  
3,264 × 2,448;  
1.39 MB



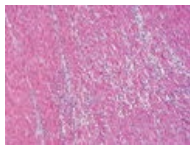
Infarkt ledviny (2...  
3,264 × 2,448;  
5.08 MB



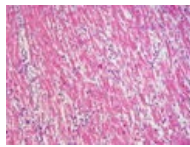
Infarkt ledviny (2...  
3,264 × 2,448;  
4.43 MB



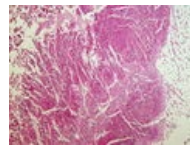
Infarkt myokardu...  
3,264 × 2,448;  
4.56 MB



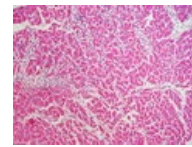
Infarkt myokardu...  
3,264 × 2,448;  
4.56 MB



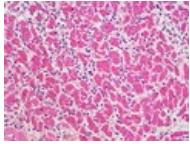
Infarkt myokardu...  
3,264 × 2,448; 3.6  
MB



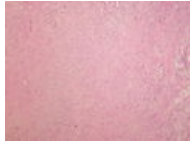Infarkt myokardu...  
3,264 × 2,448;  
4.43 MB



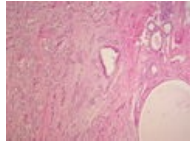
Infarkt myokardu...  
3,264 × 2,448;  
3.62 MB



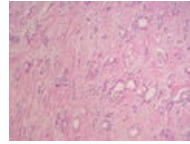
Infarkt myokardu...  
3,264 × 2,448;  
3.41 MB



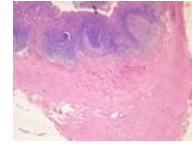
Infiltrující karcino...  
3,264 × 2,448;  
3.71 MB



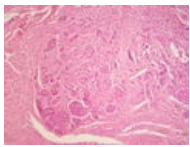
Infiltrující karcino...  
3,264 × 2,448;  
3.54 MB



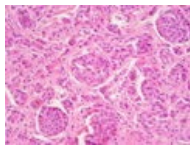
Infiltrující karcino...  
3,264 × 2,448;  
3.91 MB



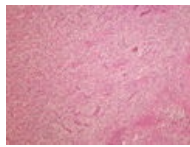
Karcinoid append...  
3,264 × 2,448;  
1.35 MB



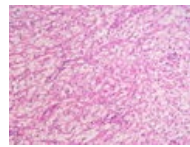
Karcinoid append...  
3,264 × 2,448;  
1.36 MB



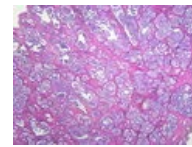
Karcinoid append...  
3,264 × 2,448;  
1.42 MB



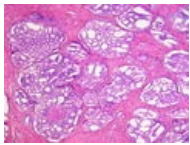
Karcinom ledviny...  
3,264 × 2,448;  
1.36 MB



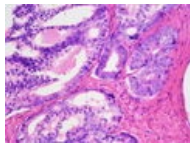
Karcinom ledviny...  
3,264 × 2,448; 1.4  
MB



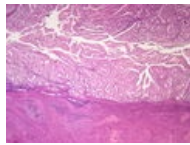
Karcinom prostat...  
3,264 × 2,448;  
1.37 MB



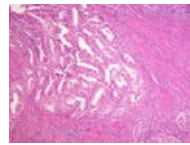
Karcinom prostat...  
3,264 × 2,448;  
1.76 MB



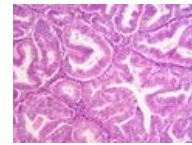
Karcinom prostat...  
3,264 × 2,448;  
1.53 MB



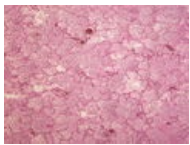
Karcinom těla děl...  
3,264 × 2,448;  
1.64 MB



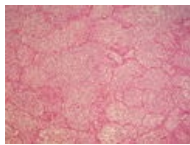
Karcinom těla děl...  
3,264 × 2,448;  
1.67 MB



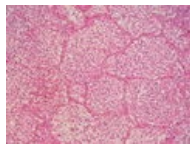
Karcinom těla děl...  
3,264 × 2,448;  
1.62 MB



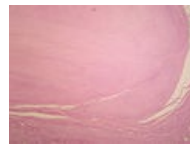
Katarální bronch...  
3,264 × 2,448;  
1.31 MB



Katarální bronch...  
3,264 × 2,448;  
1.85 MB



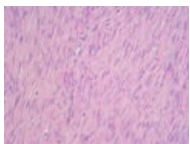
Katarální bronch...  
3,264 × 2,448;  
1.64 MB



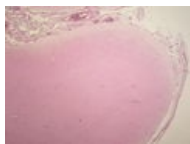
Leiomyoma uteri ...  
3,264 × 2,448;  
1.39 MB



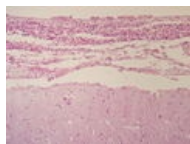
Leiomyoma uteri ...  
3,264 × 2,448;  
1.48 MB



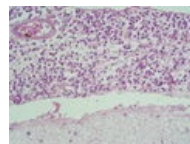
Leiomyoma uteri ...  
3,264 × 2,448;  
1.56 MB



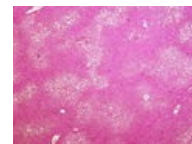
Leptomeningitis ...  
3,264 × 2,448;  
1.59 MB



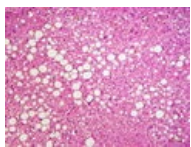
Leptomeningitis ...  
3,264 × 2,448;  
1.47 MB



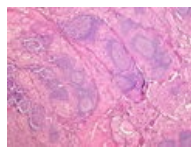
Leptomeningitis ...  
3,264 × 2,448; 1.6  
MB



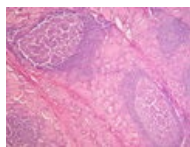
Ložisková velkok...  
3,264 × 2,448;  
4.71 MB



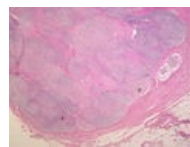
Ložisková velkok...  
3,264 × 2,448;  
3.62 MB



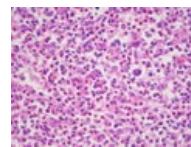
Lymfoplasmocyt...  
3,264 × 2,448;  
3.92 MB



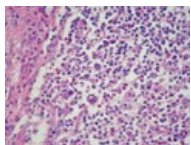
Lymfoplasmocyt...  
3,264 × 2,448;  
4.29 MB



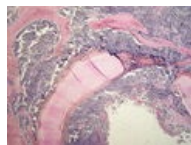Maligní lymfogra...  
3,264 × 2,448;  
1.29 MB



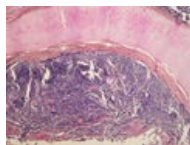
Maligní lymfogra...  
3,264 × 2,448;  
1.67 MB



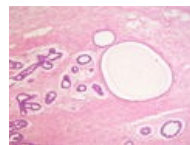
Maligní lymfogra...  
3,264 × 2,448;  
1.59 MB



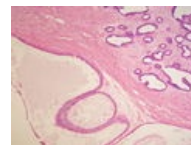
Malobuněčný kar...  
3,264 × 2,448;  
1.91 MB



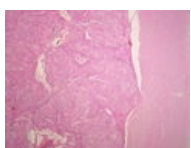
Malobuněčný kar...  
3,264 × 2,448;  
1.31 MB



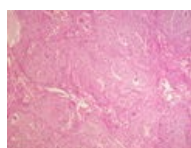
Mastopathia fibro...  
3,264 × 2,448; 1.5  
MB



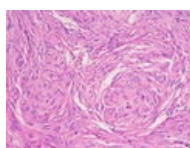
Mastopathia fibro...  
3,264 × 2,448;  
1.54 MB



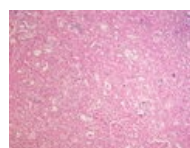
Meningeom (69A...  
3,264 × 2,448;  
1.54 MB



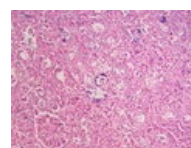
Meningeom (69B...  
3,264 × 2,448;  
1.65 MB



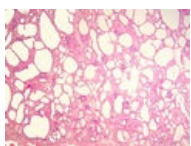
Meningeom (69C...  
3,264 × 2,448;  
1.39 MB



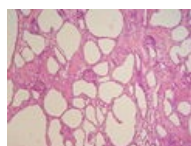
Metastatické zvá...  
3,264 × 2,448;  
1.37 MB



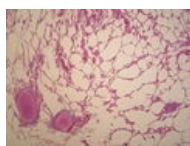
Metastatické zvá...  
3,264 × 2,448;  
1.54 MB



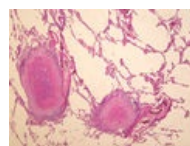
Mikrocystóza led...  
3,264 × 2,448;  
2.34 MB



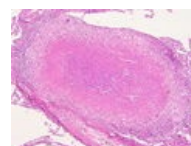
Mikrocystóza led...  
3,264 × 2,448;  
3.05 MB



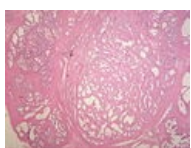
Miliární TBC plic (...  
3,264 × 2,448; 1.5  
MB



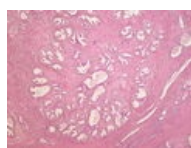
Miliární TBC plic (...  
3,264 × 2,448;  
1.93 MB



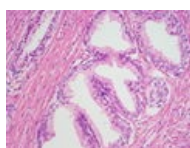
Miliární TBC plic (...  
3,264 × 2,448;  
1.74 MB



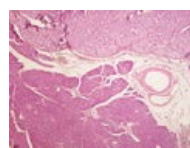
Myoadenomová ...  
3,264 × 2,448;  
1.66 MB



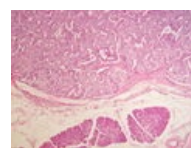
Myoadenomová ...  
3,264 × 2,448; 1.3  
MB



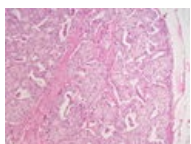
Myoadenomová ...  
3,264 × 2,448;  
1.53 MB



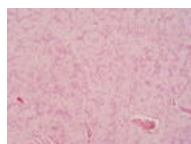
Nesidiom (79A).jpg  
3,264 × 2,448;  
4.35 MB



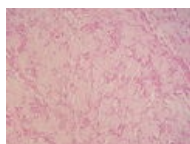
Nesidiom (79B).jpg  
3,264 × 2,448; 4  
MB



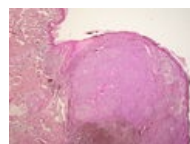
Nesidiom (79C).jpg  
3,264 × 2,448;  
1.46 MB



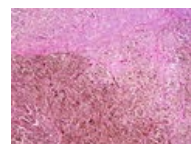
Neurilemom (25A...  
3,264 × 2,448;  
1.38 MB



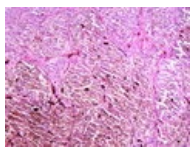
Neurilemom (25B...  
3,264 × 2,448;  
1.51 MB



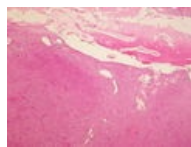
Nodulární melan...  
3,264 × 2,448;  
4.44 MB



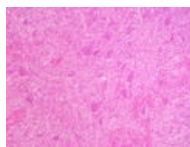
Nodulární melan...  
3,264 × 2,448; 1.3  
MB



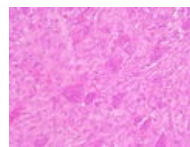
Nodulární melan...  
3,264 × 2,448;  
1.79 MB



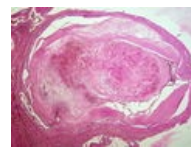
Obrovskobuněčn...  
3,264 × 2,448;  
3.97 MB



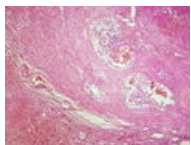
Obrovskobuněčn...  
3,264 × 2,448;  
1.44 MB



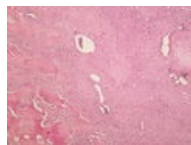
Obrovskobuněčn...  
3,264 × 2,448;  
1.52 MB



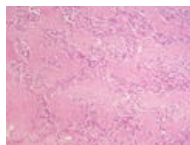
Organizovaný tro...  
3,264 × 2,448;  
3.62 MB



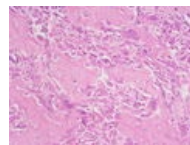
Organizovaný tro...  
3,264 × 2,448;  
3.64 MB



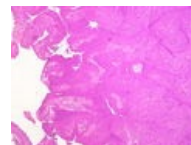
Osteosarkom (72...  
3,264 × 2,448;  
1.38 MB



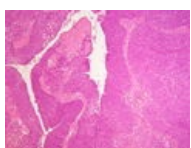
Osteosarkom (72...  
3,264 × 2,448;  
1.46 MB



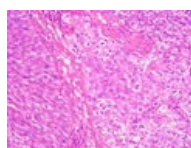
Osteosarkom (72...  
3,264 × 2,448;  
1.69 MB



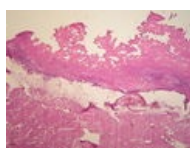
Papilokarcinom ...  
3,264 × 2,448;  
1.35 MB



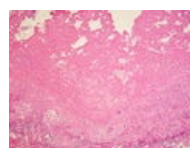
Papilokarcinom ...  
3,264 × 2,448;  
1.36 MB



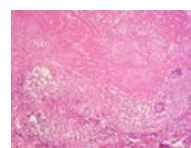
Papilokarcinom ...  
3,264 × 2,448;  
1.43 MB



Pericarditis TBC (...  
3,264 × 2,448;  
1.58 MB



Pericarditis TBC (...  
3,264 × 2,448;  
1.39 MB



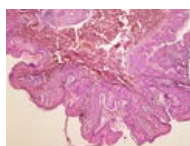
Pericarditis TBC (...  
3,264 × 2,448;  
1.35 MB



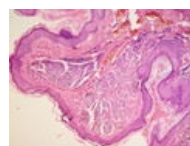
Perisplenitis carti...  
3,264 × 2,448;  
3.03 MB



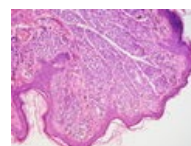
Perisplenitis carti...  
3,264 × 2,448;  
4.27 MB



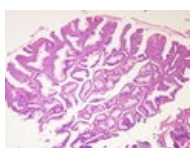
Pigmentový névu...  
3,264 × 2,448;  
1.78 MB



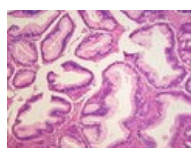
Pigmentový névu...  
3,264 × 2,448;  
1.38 MB



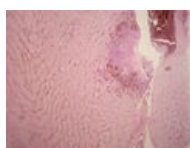Pigmentový névu...  
3,264 × 2,448;  
1.48 MB



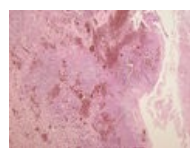Polypózní adeno...  
3,264 × 2,448;  
1.39 MB



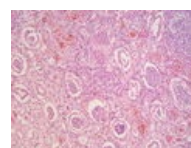
Polypózní adeno...  
3,264 × 2,448;  
1.42 MB



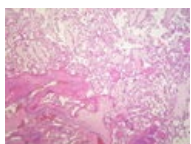
Pyelonefritis hnis...  
3,264 × 2,448; 1.4  
MB



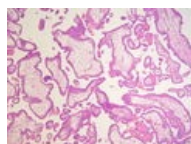
Pyelonefritis hnis...  
3,264 × 2,448;  
1.88 MB



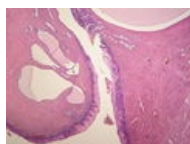
Pyelonefritis hnis...  
3,264 × 2,448;  
1.55 MB



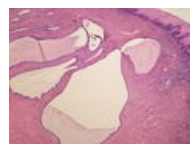Residua post abo...  
3,264 × 2,448;  
1.66 MB



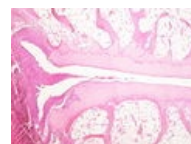
Residua post abo...  
3,264 × 2,448;  
1.47 MB



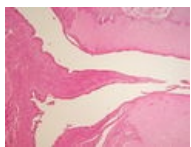Retenční cysty c...  
3,264 × 2,448;  
1.55 MB



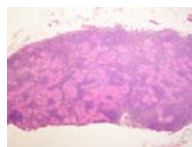
Retenční cysty c...  
3,264 × 2,448;  
1.63 MB



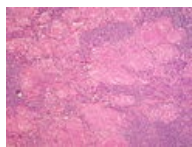
Revmatoidní artrii...  
3,264 × 2,448;  
1.42 MB



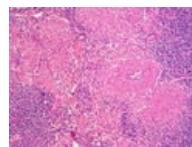
Rheumatoidní artritida...  
3,264 × 2,448;  
1.54 MB



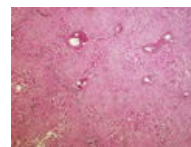
Sarkoidóza uzliny...  
3,264 × 2,448;  
1.72 MB



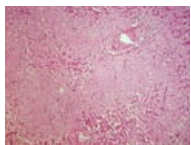
Sarkoidóza uzliny...  
3,264 × 2,448;  
1.54 MB



Sarkoidóza uzliny...  
3,264 × 2,448;  
1.84 MB



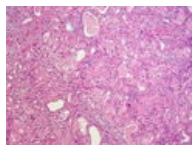
Sekundární amyloidóza...  
3,264 × 2,448;  
3.83 MB



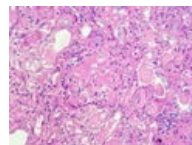
Sekundární amyloidóza...  
3,264 × 2,448; 3.7 MB



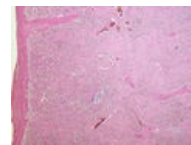
Sekundární amyloidóza...  
3,264 × 2,448;  
4.41 MB



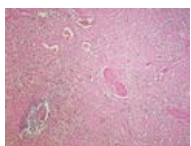
Sekundární amyloidóza...  
3,264 × 2,448;  
3.58 MB



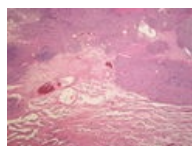
Sekundární amyloidóza...  
3,264 × 2,448;  
3.28 MB



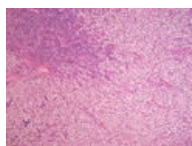
Sekundární amyloidóza...  
3,264 × 2,448;  
3.98 MB



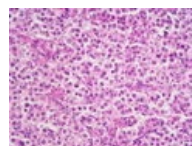
Sekundární amyloidóza...  
3,264 × 2,448;  
4.41 MB



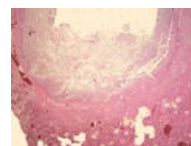
Seminom varlete...  
3,264 × 2,448;  
1.31 MB



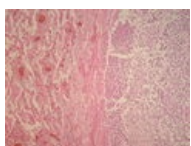
Seminom varlete...  
3,264 × 2,448; 1.3 MB



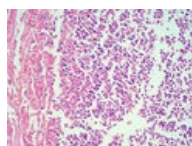
Seminom varlete...  
3,264 × 2,448;  
1.49 MB



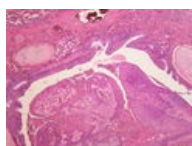
Septické metastázy...  
3,264 × 2,448;  
2.78 MB



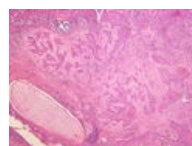
Septické metastázy...  
3,264 × 2,448;  
1.36 MB



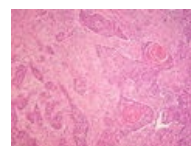
Septické metastázy...  
3,264 × 2,448;  
2.17 MB



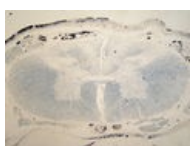Spinocelulární karcinom...  
3,264 × 2,448; 1.3 MB



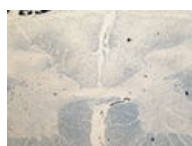Spinocelulární karcinom...  
3,264 × 2,448;  
1.31 MB



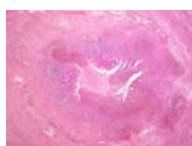
Spinocelulární karcinom...  
3,264 × 2,448;  
1.36 MB



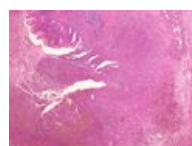Tabes dorsalis (6th stage)...  
3,264 × 2,448;  
1.49 MB



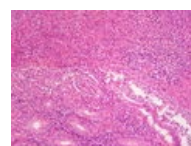
Tabes dorsalis (6th stage)...  
3,264 × 2,448;  
1.36 MB



Ulceroflegmonóza...  
3,264 × 2,448;  
1.56 MB



Ulceroflegmonóza...  
3,264 × 2,448;  
1.37 MB



Ulceroflegmonóza...  
3,264 × 2,448;  
1.74 MB

(previous page) (next page)